

# Alleviation of Histopathologic Effects of Avian Influenza Virus by a Specific Nutrient Synergy

Elie K. Barbour, PhD<sup>1</sup>  
Edward G. Rayya, BSc<sup>1</sup>  
Houssam Shaib, MSc<sup>1</sup>  
Rindala G. El Hakim, BSc<sup>1</sup>  
Aleksandra Niedzwiecki, PhD<sup>2</sup>  
Afif M. Abdel Nour, MSc<sup>3</sup>  
Steve Harakeh, PhD<sup>2</sup>  
Matthias Rath, PhD<sup>2</sup>

<sup>1</sup>*Department of Animal Science  
Faculty of Agricultural and Food Sciences  
American University of Beirut  
Beirut, Lebanon*

<sup>2</sup>*Dr. Rath Research Institute B.V.  
Santa Clara, California, USA*

<sup>3</sup>*Institut Polytechnique LaSalle Beauvais  
Beauvais, France*

**KEY WORDS:** histopathology, respiratory system, avian influenza virus, nutrient synergy

## ABSTRACT

This study aimed at alleviating the histopathologic effects of avian influenza virus by a specific nutrient synergy present in Epican Forte® (EF). The daily administration of EF at the level of 48.8 mg/mL/bird between 7-14 days of age, to birds challenged at 7-days old with H9N2-avian influenza virus, had different impacts on tracheal deciliation, goblet cell degeneration, mucus accumulation, hypertrophy of mucosal layer, and counts of tracheal heterophils and specific heterophils containing inclusion bodies. Other different impacts by EF were observed in histopathology observations of thoracic air sacs and lungs. The 2 most apparent significant reductions in tracheal histopathologic effects ( $P < 0.05$ ) due to EF administration were the mucus accumulation and the drop in specific heterophils mani-

festing a presence of inclusion bodies.

## INTRODUCTION

The Epican Forte® (EF) is a blend of pure molecules needed by different metabolic pathways in the body.<sup>1-3</sup> It is a preparation that contains standardized green tea extract (23.6%), vitamin C (16.8%), L-lysine (23.6%), L-proline (17.7%), L-arginine (11.8%), N-acetyl cysteine (4.7%), copper (0.05%), manganese (0.02%), and selenium (trace).

The green tea extract contains the epigallocatechin gallate (EGCG)-active ingredient, that has antioxidant and anticarcinogenic properties.<sup>1-3</sup> EGCG has also an antiviral effect on influenza virus subtypes as documented by Song et al<sup>4</sup> who suggested that the antiviral effect of EGCG on influenza virus is mediated by specific interaction with the hemagglutinin (HA) protein altering the physical properties of the viral coat, and by suppressing viral RNA synthesis in Madin-Darby canine kidney (MDCK) cells.

Vitamin C is a strong antioxidant playing an important role in stabilizing the connective tissue by supporting collagen production.<sup>5</sup> Vitamin C is also known to have an antiviral effect on influenza virus as demonstrated by Gorton and Jarvis<sup>6</sup> who found that mega-doses of vitamin C had an 85% prevention and relief rate of cold and flu symptoms in students 18 to 30 years of age. Vitamin C in combination with vitamin E has stronger effects on reduction of influenza virus infectivity probably through vitamin C's repairing effect on vitamin E's tocopheroxyl compound.<sup>7</sup>

The antioxidant properties of EGCG and vitamin C could play an important role in the antiviral effect against influenza virus. In fact, Hennes et al<sup>8</sup> demonstrated that oxidant-treated anti-protease is unable to prevent trypsin from cleaving the hemagglutinin protein (HA0) to HA1/HA2, resulting in a 10,000-fold increase in infectious influenza virus. As a protective effect, anti-proteases are present on the surface of alveoli and are inactivated by reactive oxygen species (ROS); consequently, the use of an antioxidant would be of primary importance to reactivate anti-protease to prevent influenza viral infections.<sup>9,10</sup>

Lysine, proline, and arginine showed anticarcinogenic effects along with vitamin C and EGCG against fibrosarcoma cells H7-1080,<sup>3</sup> human breast cancer lines MDA-MB-231 and MCF-7,<sup>2</sup> and against human prostate cancer.<sup>1</sup> However, literature citation of the antiviral effect of amino acids supplementation in diets is still meager. N-acetyl cysteine significantly decreased the mortality in influenza-infected mice.<sup>11</sup> A combination of N-acetyl cysteine with ribavirin had a synergistic effect in protection against lethal influenza viral infection in mouse.<sup>12</sup>

Beauman<sup>13</sup> reported that L-lysine could be an alternative therapy against genital herpes, while Orzechowska et al<sup>14</sup> observed that the addition of proline-rich polypeptide to resident peritoneal cells from female mice infected with vesicular stomatitis virus inhibits the viral replication and drops its titer by 4 units on the logarithmic scale.

The effect against influenza virus was also shown by elements present in EF such as selenium and copper. In fact, selenium deficiency increases the pathogenicity of influenza virus infection in mice.<sup>15</sup> The increased oxidative stress due to influenza virus infection in selenium deficient mice leads to an increased NF- $\kappa$ B expression leading to an enhanced type 2 helper T-cell response, which results in increased lung inflammation; however, mice with adequate selenium intake showed a type 1 helper T-cell response after an influenza virus infection, leading to lower pathogenicity effect. Copper manifested an anti-influenza A effect through inhibition of the proton translocation machinery in M2 protein of this virus.<sup>16</sup> Moreover, according to Nagayama,<sup>17</sup> cloth dyed with a combination of gentiane-violet and copper showed a significant antiviral activity against influenza A virus.

The purpose of this study is to determine the impact of EF on alleviation of tracheal, thoracic air sac, and lung histopathologic lesions caused by a controlled challenge of H9N2-avian influenza virus (AIV).

## **MATERIALS AND METHODS**

### **Birds**

Sixty meat-type 1-day-old chicks were divided into 3 groups of 20 birds/group. Each group was reared in a separate isolation room, with similar environmental conditions, same availability of feeders and drinkers, and offered feed and drinking water ad libitum according to the National Research Council requirements.<sup>18</sup>

### **Avian Influenza Challenge and EF Treatment**

Birds in the 3 groups were reared similarly until the age of 6 days. Each bird in groups 2 and 3 received at 7 days of age a similar challenge of H9N2-AIV. Briefly, each bird received intraesophageally a volume of 0.5 mL of chick embryo allantoic fluid containing 2 HA units of the virus, equivalent to around  $2.0 \times 10^7$  H9N2 viable viral particles of the virus. Birds of group 1 were left without challenge or treatment (controls).

Birds of group 3 were the only ones that received treatment with EF, on a daily basis, between the age of 7-14 days, and in a volume of 1 mL/bird administered intra-esophageally. The dosing of EF was set at 48.8 mg/mL/bird/day.

### Protection Against AIV

Microscopic lesions were observed at 14 days of age and in 3 organs of each bird, namely the trachea, thoracic air sac, and lung. Briefly, each survived bird was sacrificed at 14 days of age by CO<sub>2</sub> asphyxiation. Each of the 3 organs was sampled aseptically and kept in 10% formalin-supplemented phosphate-buffered saline. All collected organs were forwarded to the Immuno-Histochemistry Department at the American University Hospital in Beirut, Lebanon. Four histologic sections were cut randomly from each trachea and lung, while 3 sections were prepared of each air sac. The sections were fixed on charged microscopic slides, followed by H&E staining procedure.<sup>19</sup>

Each of the 4 sections of a tracheal organ was observed at 3 fields located at 4, 8, and 12 o'clock positions using a microscope-magnification of 400×, resulting in observation of 3 fields/section × 4 sections/trachea = 12 fields/trachea/bird. Presence of lesions in the 12 fields was added for each bird to allow calculating the average presence of the lesion per group or treatment. The observed microscopic lesions of the trachea included deciliation, goblet cell degeneration, mucus accumulation, hypertrophy of mucosal layer, and heterophil count. An additional observation was recorded at a magnification of 1000× searching for the presence of inclusion bodies inside each encountered heterophil in the 12 fields/trachea/bird.

Each of the 3 sections of the thoracic air sac or lung was observed at 3 randomly chosen fields and at a magnification of 400× recording hypertrophy of mucosal layer in air sacs, mucosal exudates accumulation in lung air ducts, and heterophil count in both. The observation and counting of heterophils containing inclusion bodies was accomplished at a magnification of 1000×. Thus,

the cumulative recording of each observation in air sac or lung was obtained from 3 fields/section × 3 sections/air sac or lung = 9 fields/air sac or lung/bird.

### Statistics

The average of a measured parameter was compared among the 3 groups using the one-way ANOVA. Significant differences in the measured parameter were determined at  $P = 0.05$ . The SPSS v.14 program was used in statistical computing of the data.

### RESULTS AND DISCUSSION

The weighted different histopathologic lesions recorded at 14 days of age in tracheas, thoracic air sacs, and in lungs are shown in Tables 1, 2, and 3 respectively. The histopathologic lesions of the tracheas showed a significant reduction in mucus accumulation and in presence of heterophilic inclusion bodies of EF-treated birds of group 3 in comparison to EF-deprived and H9N2-challenged birds of group 2 ( $P < 0.05$ ) and to control birds of group 1 ( $P < 0.05$ ) (Table 1).

This indicates that the components of EF were effective in clearing the air passage of the trachea from mucus (Figures 1 and 2), and in possible activation of the heterophils, increasing their ability in phagocytosis, and in enzymatic catabolism of the H9N2 particles, which is shown in lower presence of inclusion bodies in these phagocytic cells (Figures 3 and 4).

It is worth noting that there was no difference between EF-treated (group 3) and EF-deprived (group 2) birds in the other observed microscopic histopathologic lesions of trachea namely, deciliation, goblet cell degeneration, hypertrophy of mucosal layer, mucus accumulation, and heterophil count ( $P > 0.05$ ) (Table 1); in addition, the control birds were having almost non-presence of any of the 6 histopathologic observations.

The weighted histopathologic lesions in the thoracic air sac of birds in the 3 groups are presented in Table 2.

One out of 3 histopathologic observations, namely the heterophil count in air

**Table 1.** Average Cumulative Score or Count of Deciliation, Goblet Cell Degeneration, Mucus Accumulation, Hypertrophy of Mucosal Layer, Heterophil, and Inclusion Body-Associated Heterophil in the Trachea of Different Groups of Birds.

| Group* | Average Cumulative Scores or Counts†/Slide/4 Cuts |                                  |                            |                                    |                    |  |
|--------|---|----------------------------------|----------------------------|------------------------------------|--------------------|--|
|        | Decilia-<br>tion                                  | Goblet Cell<br>Degenera-<br>tion | Mucus<br>Accumula-<br>tion | Hypertrophy<br>of Mucosal<br>Layer | Counts             |  |
|        |   |                                  |                            |                                    | Heterophil         | Heterophils<br>With Inclu-<br>sion Bodies‡ |
| 1      | 0.47 <sup>a</sup>                                 | 0.89 <sup>a</sup>                | 0.37 <sup>a</sup>          | 0.00 <sup>a</sup>                  | 0.00 <sup>a</sup>  | 0.00 <sup>a</sup>                          |
| 2      | 10.94 <sup>b</sup>                                | 10.7 <sup>b</sup>                | 9.88 <sup>c</sup>          | 9.94 <sup>b</sup>                  | 43.94 <sup>a</sup> | 5.88 <sup>c</sup>                          |
| 3      | 10.61 <sup>b</sup>                                | 10.84 <sup>b</sup>               | 7.70 <sup>b</sup>          | 8.92 <sup>b</sup>                  | 32.38 <sup>a</sup> | 2.70 <sup>b</sup>                          |

\*Birds of group 1 were left without medication and without AIV challenge, group 2 was left without medication and challenged intratracheally with 0.5 mL of 2 HA units of AIV, and group 3 was given EF from 7 to 14 days of age and challenged intratracheally with 0.5 mL of 2 HA units of AIV.

†Average cumulative score or count in 12 tracheal fields (4 cuts × 3 fields/cut).

‡All observations done at 400× in the designated fields/cut, except when encountering a heterophil, the objective is changed to oil-immersion with magnification of 1000× to detect the presence of heterophilic inclusion bodies (IB). A presence of IB in a heterophil is recorded as 1, and absence as zero. All numbers are added for all cuts and fields to report the number of heterophils containing IB/sample/bird.

<sup>a,b,c</sup>Averages with different superscripts in a column are significantly different ( $P < 0.05$ ).

**Table 2.** Average Cumulative Hypertrophy Score of Mucosal Layer, Heterophil, and Inclusion Body-Associated Heterophil Count in the Air Sacs of Different Groups of Birds.

| Group* | Average Cumulative Score or Count†/3 Cuts × 3 Fields |                      |   |
|--------|--|----------------------|---|
|        | Hypertrophy of<br>Mucosal Layer                      | Count                |   |
|        |  | Heterophil           | Heterophils With Inclu-<br>sion Bodies‡ |
| 1      | 0.37 <sup>a</sup>                                    | 0.00 <sup>a</sup>    | 0.00 <sup>a</sup>                       |
| 2      | 3.29 <sup>b</sup>                                    | 44.64 <sup>a,b</sup> | 5.53 <sup>b</sup>                       |
| 3      | 2.46 <sup>b</sup>                                    | 53.54 <sup>b</sup>   | 6.00 <sup>b</sup>                       |

\*Birds of group 1 were left without medication and without AIV challenge, group 2 was left without medication and challenged intratracheally with 0.5 mL of 2 HA units of AIV, and group 3 was given EF from 7 to 14 days of age and challenged intratracheally with 0.5 mL of 2 HA units of AIV.

†Average cumulative score or count in 9 tracheal fields (3 cuts × 3 fields/cut).

‡All observations done at 400× in the designated fields/cut, except when encountering a heterophil, the objective is changed to oil-immersion with magnification of 1000× to detect the presence of heterophilic inclusion bodies (IB). A presence of IB in a heterophil is recorded as 1, and absence as zero. All numbers are added for all cuts and fields to report the number of heterophils containing IB/sample/bird.

<sup>a,b,c</sup>Averages with different superscripts in a column are significantly different ( $P < 0.05$ ).

**Table 3.** Average Cumulative Score or Count of Hypertrophy of Mucosal Layer, Heterophil Counts, and Heterophilic Inclusion Body Areas in the Lung in Different Groups of Birds.

| Group* | Average Cumulative Score or Count†/3 Cuts × 3 Fields |                      |   |
|--------|--|----------------------|---|
|        | Mucosal Exudates in<br>Air Ducts                     | Count                |   |
|        |  | Heterophil           | Heterophils With Inclu-<br>sion Bodies‡ |
| 1      | 0.37 <sup>a</sup>                                    | 0.00 <sup>a</sup>    | 0.00 <sup>a</sup>                       |
| 2      | 3.29 <sup>b</sup>                                    | 44.64 <sup>a,b</sup> | 5.53 <sup>b</sup>                       |
| 3      | 2.46 <sup>b</sup>                                    | 53.54 <sup>b</sup>   | 6.00 <sup>b</sup>                       |

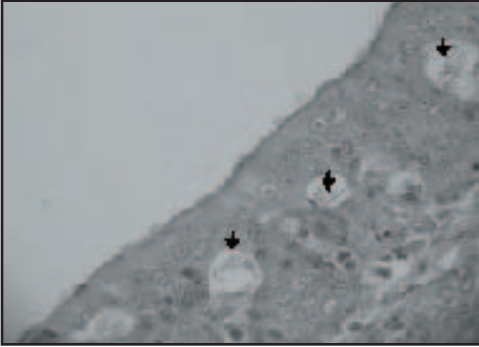
\*Birds of group 1 were left without medication and without AIV challenge, group 2 was left without medication and challenged intratracheally with 0.5 mL of 2 HA units of AIV, and group 3 was given EF from 7 to 14 days of age and challenged intratracheally with 0.5 mL of 2 HA units of AIV.

†Average cumulative score or count in 9 tracheal fields (3 cuts × 3 fields/cut).


‡All observations done at 400× in the designated fields/cut, except when encountering a heterophil, the objective is changed to oil-immersion with magnification of 1000× to detect the presence of heterophilic inclusion bodies (IB). A presence of IB in a heterophil is recorded as 1, and absence as zero. All numbers are added for all cuts and fields to report the number of heterophils containing IB/sample/bird.

<sup>a,b,c</sup>Averages with different superscripts in a column are significantly different ( $P < 0.05$ ).

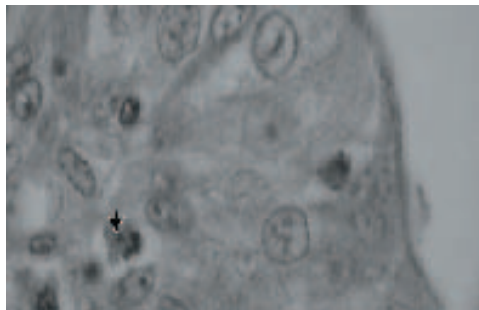
**Figure 1.** Goblet cells degeneration areas and mucus accumulation (arrow head) in the trachea of birds from group 2 challenged with AIV and deprived of EF administration (400×).




**Figure 2.** Absence of Goblet cell degeneration and mucus accumulation areas in the trachea of birds in the control group (400×).



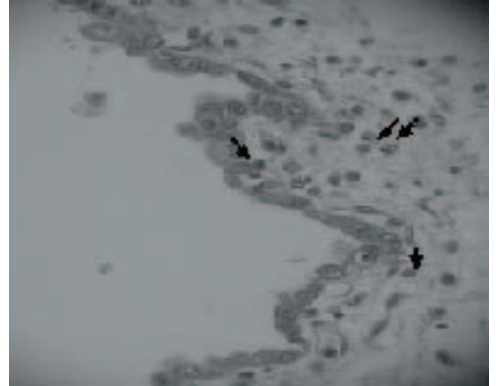
**Figure 3.** Fewer heterophilic inclusion bodies (arrow head) in the tracheal mucosal layer of birds from group 3 challenged with AIV and administered EF (1000×).



**Figure 4.** Presence of numerous heterophilic inclusion bodies (arrow head) in the tracheal mucosal layer of birds from group 2 challenged with AIV and deprived of EF administration (1000×).



**Figure 5.** Generous presence of heterophils (arrow head) in the air sac of birds from group 3 challenged with AIV and administered EF (400×).



**Figure 6.** Absence of heterophils in the air sac of birds in the control groups (400×).

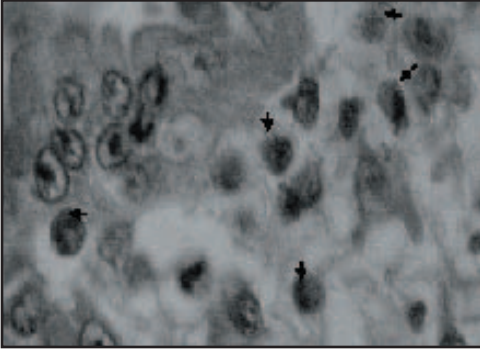


sac, is worth commenting on: the count was more than double in the EF-treated birds of group 3 in comparison to that of EF-deprived birds of group 2, with a significant higher count in group 3 (Figure 5) in comparison to controls ( $P < 0.05$ ) (Figure 6).


The raise in heterophil counts of EF-deprived and H9N2-challenged birds of group 2 was insignificantly different than that of the control ( $P > 0.05$ ). This observation shows that the components of EF had the ability to increase the chemotactic ability of phagocytic heterophils towards the thoracic



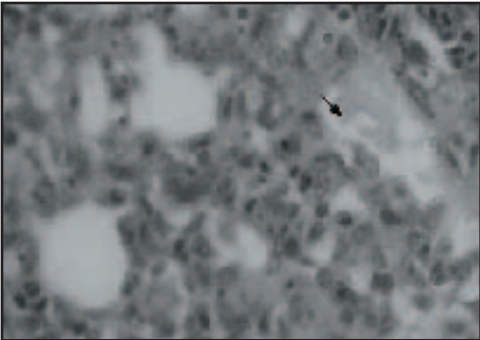
**Figure 7.** Presence of mucosal exudates (arrow head) in the air ducts of the lung in birds of group 2 challenged with AIV and deprived of EF administration (400×).



**Figure 8.** Presence of heterophilic inclusion bodies (arrow head) in the air sac of birds from group 3 challenged with AIV and administered EF (1000×).

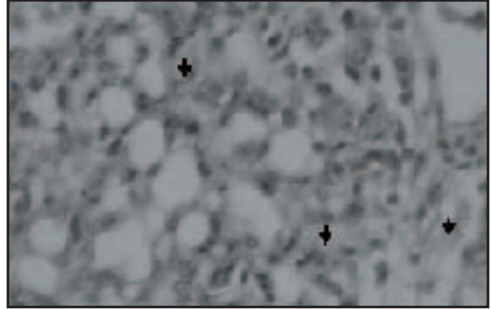


**Figure 9.** Presence of mucosal exudates (arrow head) in the air ducts of the lung in birds of group 2 challenged with AIV and deprived of EF administration (400×).

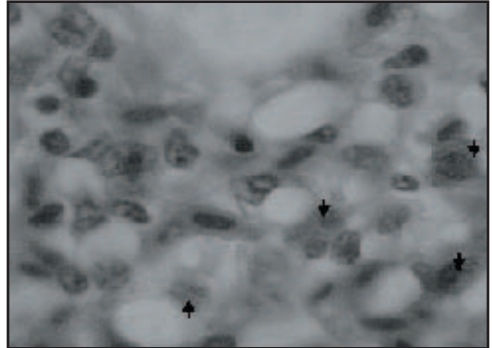


air sac in birds of group 3, which most likely reduces the density of the H9N2 infiltrating this part of the respiratory system. The other 2 weighted histopathologic observations, namely the hypertrophy of the mucosal layer and presence of heterophilic inclusion bodies, did not differ between the EF-treated and EF-deprived challenged birds ( $P > 0.05$ )

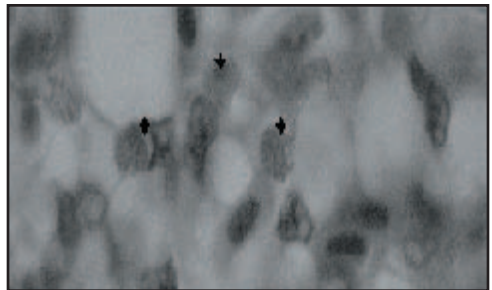
**Figure 10.** Presence of mucosal exudates (arrow head) in the air ducts of the lung in birds of group 3 challenged with AIV and administered EF (400×).



**Figure 11.** Generous presence of heterophilic inclusion bodies (arrow head) in the lung of birds of group 3 challenged with AIV and administered EF (1000×).



**Figure 12.** Generous presence of heterophilic inclusion bodies (arrow head) in the lung of birds of group 2 challenged with AIV and deprived of EF administration (1000×).



(Figures 7 and 8), but had a significantly higher weight when compared to controls ( $P < 0.05$ ) (Table 2).

The weighted histopathologic lesions in the trachea of birds in the 3 groups are shown in Table 1. Mucosal exudate accumulation in air ducts of the lung was high in both challenged groups 2 and 3 (Table

3; Figures 9 and 10) in comparison to that observed in the trachea (Table 1).

This difference in histopathologic observation of the lung and trachea is most likely due to the difference in pathogenesis of H9N2 virus on different organs of the respiratory system of birds, which is most likely affected by the nature of structure of these organs. There was a generous presence of heterophilic inclusion bodies in lungs of EF-treated (Figure 11) and EF-deprived (Figure 12; Table 3) challenged birds in comparison of such a presence in the air sacs of birds belonging to groups 2 and 3 (Table 2).

This indicates that the catabolism of viral inclusion bodies in the lung (Table 3) is less efficient than that of the air sacs (Table 2). However, the EF did prove its only significant efficacy in clearing the viral inclusions in heterophils present in the trachea of birds in group 3 ( $P < 0.05$ ) in comparison to EF-deprived birds of group 2 (Table 1).

In conclusion, data of segment 1 of this research showed that the daily oral administration of EF to birds free from AIV infection, between 7-14 days of age at 48.8 mg/mL/bird, results in improvement of body weight ( $P > 0.05$ ) and significant reduction in feed conversion ratio ( $P < 0.05$ ) at 14 days of age, associated with a significant ( $P < 0.05$ ) increase in the liver weight index, a significant increase in cecal fermentation, and complete absence of toxicity signs. This performance in body weight and feed conversion kept its improvement in EF-treated and H9N2-infected birds in comparison to EF-deprived and H9N2-infected birds, but at an insignificant statistical level of  $P = 0.05$  (segment 2 of this research). The other data of segment 2 of this research indicates that the EF treatment had significant ( $P < 0.05$ ) improvements in the following parameters, namely signs (absence of rales at 3 days post H9N2 challenge), gross lesions (absence of tracheitis and enteritis at 7 days post challenge), and in significant reduction of the following histopathologic parameters, namely mucus accumulation and counts of inclusion bodies-associated heterophils in the trachea.

## REFERENCES

1. Roomi MW, Ivanov V, Kalinovsky T, Niedzwiecki A, Rath M: In vivo antitumor effect of ascorbic acid, lysine, proline and green tea extract on human prostate cancer PC-3 xenografts in nude mice: evaluation of tumor growth and immunohistochemistry. *In Vivo* 2005;19(1):179-183.
2. Roomi MW, Ivanov V, Kalinovsky T, Niedzwiecki A, Rath M: In vitro and vivo antitumorigenic activity of a mixture of lysine, proline, ascorbic acid, and green tea extract on human breast cancer lines MDA-MB-231 and MCF-7. *Med Oncol* 2005;22(2):129-138.
3. Roomi MW, Ivanov V, Kalinovsky T, Niedzwiecki A, Rath M: In vivo antitumor effect of ascorbic acid, lysine, proline, arginine, and green tea extract on human fibrosarcoma cells HT-1080. *Med Oncol* 2006;23(1):105-111.
4. Song JM, Lee KH, Seong BL: Antiviral effect of catechins in green tea on Influenza virus. *Antiviral Res* 2005;68(2):66-74.
5. Munday K, Fulford A, Bates CJ: Vitamin C status and collagen cross link ratios in Gambian children. *Br J Nutr* 2005;93(4):501-507.
6. Gorton HC, Jarvis K: The effectiveness of vitamin C in preventing and relieving the symptoms of virus-induced respiratory infections. *J Manipulative Physiol Ther* 1999;22(8):530-533.
7. Tantcheva LP, Stoeva ES, Galabov AS, Braykova AA, Savov VM, Mileva MM: Effect of vitamin E and vitamin C combination on experimental influenza virus infection. *Methods Find Exp Clin Pharmacol* 2003;25(4):259-264.
8. Hennet T, Ziltener HJ, Frei K, Peterhans E: A kinetic study of immune mediators in the lungs of mice infected with influenza A virus. *J Immunol* 1992;149:932-939.
9. Peterhans E: Oxidants and antioxidants in viral diseases: disease mechanisms and metabolic regulation. In: Symposium: Newly Emerging Viral Diseases: What Role for Nutrition? *J Nutr* 1997.
10. Snelgrove RJ, Edwards L, Rae AJ, Hussell T: An absence of reactive oxygen species improves the resolution of lung influenza infection. *Eur J Immunol* 2006;36(6):1364-1373.
11. Ungheri D, Pisani C, Sanson G, et al: Protective effect of N-acetyl cysteine in a model of influenza infection in mice. *Int J Immunopathol Pharmacol* 2000;13(3):123-128.
12. Ghezzi P, Ungheri D: Synergistic combination of N-acetyl cysteine and ribavirin to protect from lethal influenza viral infection in a mouse model. *Int J Immunopathol Pharmacol* 2004;17(1):99-102.
13. Beauman JG: Genital herpes: a review. *Am Fam Physician* 2005;72(8):1527-1534.
14. Orzechowska B, Janusz M, Domaraczenko B, Blach-Olszewska Z: Antiviral effect of proline-rich polypeptide in murine resident peritoneal cells. *Acta Virol* 1998;42(2):75-78.
15. Beck M, Nelson H, Shi K, et al: Selenium deficiency increases the pathology of an influenza virus infection. *FASEB J* 2001;15:1481-1483.

16. Ghandi CS, Shuck K, Lear JD, et al: Cu (II) inhibition of the proton translocation machinery of the influenza A virus by gentian violet (GV) and GV-dyed cotton cloth, and bactericidal activities of these agents. *J Infect Chemother* 1999;12(2):73-79.
17. Nagayama A: Inactivation of influenza A virus by gentian violet (GV) and GV- dyed cotton cloth, and bactericidal activities of these agents. *J Infect Chemother* 2006;12(2):73-79.
18. National Research Council: *Nutrient Requirements of Poultry*. 8th revised edition. Washington, DC: National Academy Press; 1984:11-15.
19. Luna LG: *Manual of Histologic Staining Methods of the Armed Forces Institute of Pathology*. 3rd ed. Mc New York: Graw-Hill Book Company; 1968.